

Assessment of efficacy of ultrasound in the diagnosis of peri-apical pathologies

Altaf Hussain Chalkoo¹, Inderpreet Singh Oberoi², Kuku Dhingra³

¹Professor and HOD, ²PG scholar, Department of Oral Medicine and Radiology, Government Dental College and Hospital, Srinagar³BDS, Tutor, Dasmesh Dental college, Faridkot, Punjab.

Abstract

Background: Periapical lesions (PLs) are the most frequently observed pathologies associated with alveolar bone. Ultrasound (US) is a non-invasive, inexpensive and painless imaging method. Unlike X-rays, it does not cause harmful ionizing radiation. US can be used for both hard and soft tissue detection. Hence; we planned this study to evaluate the diagnostic capability ultrasound imaging in the identifying and making differential diagnosis of PLs. **Materials & methods:** The present study included assessment of 20 patients of age 18 to 60 years who were found to have peri-apical lesions on radiograph. All the subjects underwent ultrasonographic examination. All the examinations including real-time and Color Doppler imaging were performed in the periapical area extraorally. The ultrasonographic images were analyzed based on the following principles as mentioned by previous authors. All the results were recorded and analyzed. Student t test and univariate analysis was used for the assessment of level of significance. **Results:** On histopathology examination, 18 cases were found to be peri-radicular cyst out of which 15 cases were reported to be peri-radicular cyst on ultrasonography. Correlation was found in 15 cases of peri-apical radicular cysts. In case of peri-granuloma, correlation was observed only in one case. **Conclusion:** In comparison to conventional radiography, ultrasonography appears as a better imaging modality in the diagnosis of peri-apical lesions.

Key words: Diagnosis, Peri-apical, Ultrasonography

Corresponding author: Inderpreet Singh Oberoi, PG Scholar, Department of Oral Medicine and Radiology, Government Dental College and Hospital, Srinagar

This article may be cited as: Hussain A, Oberoi IS and Dhingra K. Assessment of efficacy of ultrasound in the diagnosis of peri-apical pathologies Int J Com Health and Med Res 2017;3(1):20-23

Article Received: 04-02-17

Accepted On: 09-02-2017

INTRODUCTION

Most frequent pathologic lesions associated with alveolar bone are the periapical lesions (PLs). They occur in relation to the tissues around the apex of a tooth root, the periodontal membrane and the alveolar bone. They are usually the sequelae of pulpal inflammation or necrosis with inflammatory mediators spreading through the apical foramen to initiate a periapical lesion.^{1, 2} Colonization and proliferation of micro-organisms occurs subsequently after the pulpal necrosis within the root canal system with the release of bacteria toxins and inflammatory mediators into the periapical region.³ Ultrasound (US) is a non-invasive, inexpensive and painless imaging method. Unlike X-rays, it does not cause harmful ionizing radiation. US can be used for both hard and soft tissue detection.⁴ US is a reliable

diagnostic technique in determining the pathological nature of periapical lesions. It has been used in guided fine-needle aspiration, measurement of tongue cancer thickness, and diagnosis of metastasis to cervical lymph nodes.^{5, 6} Hence; we planned this study to evaluate the diagnostic capability ultrasound imaging in the identifying and making differential diagnosis of PLs.

MATERIALS & METHODS

The present study was conducted in the department of oral medicine of the institute and included assessment of 20 patients of age 18 to 60 years who were found to have peri-apical lesions on radiograph. Those periapical lesions which appeared as radiopaque on the radiographs were eliminated from the study group.

Examination of the lesion on ultrasonography

All the subjects underwent ultrasonographic examination using GE Logic 400 MR3 color Doppler machine having multifrequency linear transducer using 7–11 MHz frequency. Multifrequency linear transducer was used for the examination of the patients. All the examinations including real-time and Color Doppler imaging were performed in the periapical area extraorally. The ultrasonographic images were analyzed based on the following principles as mentioned by previous authors⁷:

Cystic lesion: A hypoechoic well-contoured cavity surrounded by reinforced bone walls, filled with fluid, and with no evidence of internal vascularization on color Doppler examination.

Granuloma: A poorly defined hypoechoic area, showing rich vascular supply on color Doppler examination.

Mixed lesion: Predominantly hypoechoic area with focal anechoic area, showing vascularity in some areas on color Doppler examination

All the results were recorded and analyzed. Student t test and univariate analysis was used for the assessment of level of significance.

RESULTS

Table 1 and **Graph 1** show the correlation of histological features with ultrasonographic findings. On histopathology examination, 18 cases were found to be peri-radicular cyst out of which 15 cases were reported to be peri-radicular cyst on ultra-sonography. Correlation was found in 15 cases of peri-apical radicular cysts. In case of peri-granuloma, correlation was observed only in one case.

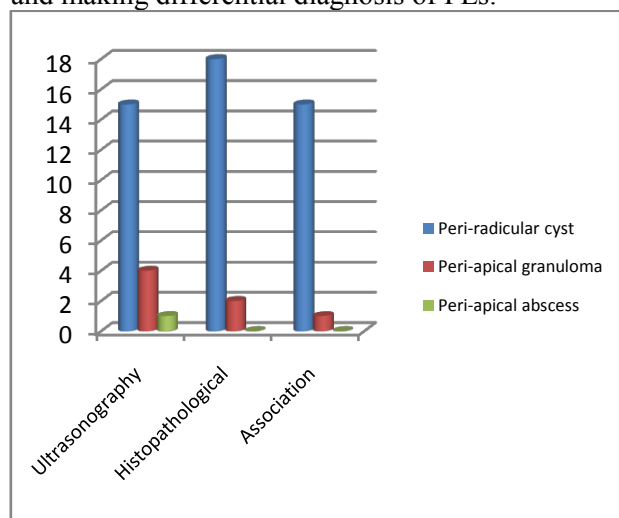
Table 1: Correlation of histological features with ultrasonographic findings

Type of lesion	Ultrasonography	H/P	Association
Peri-radicular cyst	15	18	15
Peri-apical granuloma	4	2	1
Peri-apical abscess	1	0	0

DISCUSSION

One of the key roles in the diagnosis of various peri-apical lesions is played by imaging. Periapical lesions secondary to endodontic infection are usually diagnosed and treated based on the initial radiological findings. The final confirmatory

diagnosis is performed by histopathological examination of the tissues.⁸ The majority of periapical radiolucencies of endodontic origin include periapical granuloma, periapical cyst, and periapical abscess. Conventional radiographs can only determine the mesiodistal and superoinferior extent of the pathology but not the buccolingual extent. Several radiographic features, such as the size and shape of the lesion and the presence of sclerotic border demarcating the lesion, support the diagnosis of periapical lesions.^{9, 10} Hence; we planned this study to evaluate the diagnostic capability ultrasound imaging in the identifying and making differential diagnosis of PLs.



Graph 1: Correlation of histological features with ultrasonographic findings

In the present study, we observed that approximately 80 percent of the lesions were diagnosed as peri-apical lesions on ultrasonography while more than 90 percent of the lesions were diagnosed as peri-apical lesions on histopathology. Prince et al assessed the diagnostic capability of real-time ultrasound imaging, together with the application of color power Doppler in the identification and differential diagnosis of the periapical lesions. Fifteen patients with periapical lesions of pulpal origin, diagnosed with clinical and conventional radiographic examination, were examined further using ultrasonography. The results from the biopsies of the lesions were compared and statistically analyzed. The differential diagnosis between periapical granulomas and cystic lesions, which were based on the ultrasonographic findings, were confirmed by the results of the histopathologic examination in 13 (86.7%) of 15 cases, one being granuloma and 14 being cystic lesion. Ultrasound real-time imaging is a technique that may help make a differential diagnosis between cysts and

granulomas by revealing the nature of the content of a bony lesion. This technique may have further applications in the study of other lesions of the jaws.⁷

Cotti et al assessed whether the use of real-time ultrasound imaging (echography), together with the application of 'Colour Power Doppler', can help the differential diagnosis of periapical lesions based on their contents. Eleven patients diagnosed with periapical lesions using conventional clinical and radiographic findings and who had been scheduled for endodontic surgery were examined using ultrasound imaging and Colour Power Doppler at the site of the lesions. Lesions were described in each case by an expert echographer, together with an endodontist, according to a scheme described previously. Information on the size of each lesion, its content and its vascular supply was gained and recorded by means of the ultrasound images; then, a tentative differential diagnosis between a cyst and a granuloma was made. The lesions obtained during endodontic surgery were processed and examined with a light microscope. The results from the biopsies were compared with the descriptions made with the ultrasound images. The differential diagnoses between periapical granulomas and cystic lesions, which were based on the echographic findings, were confirmed by the results of the histopathologic examination in all the 11 cases: four being granulomas and seven being cystic lesions. Ultrasound real-time imaging is a technique that may help make a differential diagnosis between cysts and granulomas by revealing the nature of the content of a bony lesion. This technique may have further applications in the study of other lesions of the jaws.¹² Goel et al evaluate the efficacy of ultrasonography (US) with color Doppler and power Doppler applications over conventional radiography in the diagnosis of periapical lesions. Thirty patients having inflammatory periapical lesions of the maxillary or mandibular anterior teeth and requiring endodontic surgery were selected for inclusion in this study. All patients consented to participate in the study. We used conventional periapical radiographs as well as US with color Doppler and power Doppler for the diagnosis of these lesions. Their diagnostic performances were compared against histopathologic examination. US examination with color Doppler and power Doppler identified 29 of 30 periapical lesions accurately, with a sensitivity of 100% for cysts and 90.91% for granulomas and a specificity of 90.91% for cysts and 100% for granulomas. In comparison, conventional intraoral radiography identified only 21 lesions. There was

definite correlation between the echotexture of the lesions and the histopathological features except in one case. US imaging with color Doppler and power Doppler is superior to conventional intraoral radiographic methods for diagnosing the nature of periapical lesions in the anterior jaws. This study revealed the potential of USG examination in the study of other jaw lesions.¹³

CONCLUSION

From the above results, the authors conclude that in comparison to conventional radiography, ultrasonography appears as a better imaging modality in the diagnosis of peri-apical lesions.

REFERENCES

1. Love RM. Bacterial penetration of the root canal of intact incisor teeth after a simulated traumatic injury. *Endod Dent Traumatol.* 1996;12: 289–293.
2. Lin LM, Huang GTJ, Rosenberg PA. Proliferation of epithelial cell rests, formation of apical cysts, and regression of apical cysts after periapical wound healing. *J Endod.* 2007;33:908–916.
3. Simon JHS, Enciso R, Malfaz J, et al. Differential diagnosis of large periapical lesions using conebeam computed tomography measurements and biopsy. *J Endod.* 2006;32(9):833–837.
4. Lia RCC, Garcia JMQ, Sousa-Neto MD, et al. Clinical, radiographic and histological evaluation of chronic periapical inflammatory lesions. *J Appl Oral Sci.* 2004;12(2):117–120.
5. Stockdale CR, Chandler NP. The nature of periapical lesion a review of 1108 cases. *J Dent Res.* 1988;16: 123–129.
6. Vier FV, Figueiredo JAP. Prevalence regarding the type of periapical pathology in 102 human teeth extracted with associated periapical lesion. *Ecler Endod.* 2000;2(2):1–15.
7. Prince CN, Annapurna CS, Sivaraj S, Ali IM. Ultrasound imaging in the diagnosis of periapical lesions. *Journal of Pharmacy & Bioallied Sciences.* 2012;4(Suppl 2):S369-S372.
8. Fernandes M, Ataide I. Non-surgical management of a large periapical lesion using a simple aspiration technique: A case report. *Int Endod J.* 2010;43:536–42.
9. Sjögren U, Figdor D, Spångberg L, Sundqvist G. The antimicrobial effect of calcium hydroxide as a short-term

- intracanal dressing. Int Endod J. 1991;24:119–25.
10. Stuart KG, Miller CH, Brown CE, Jr, Newton CW. The comparative antimicrobial effect of calcium hydroxide. Oral Surg Oral Med Oral Pathol. 1991;72:101–4.
 11. Holland R, Soares IJ, Soares IM. Influence of irrigation and intracanal dressing on the healing process of dogs' teeth with apical periodontitis. Endod Dent Traumatol. 1992;8:223–9.
 12. Cotti E, Campisi G, Ambu R, Dettori C. Ultrasound real-time imaging in the differential diagnosis of periapical lesions. Int Endod J. 2003 Aug;36(8):556-63.
 13. Goel S, Nagendrareddy SG, Raju MS, et al. Ultrasonography with color Doppler and power Doppler in the diagnosis of periapical lesions. The Indian Journal of Radiology & Imaging. 2011;21(4):279-283.

Source of support: Nil

Conflict of interest: None declared

This work is licensed under CC BY: *Creative Commons Attribution 4.0 License.*